

## An open study to determine the efficacy of blue light in the treatment of mild to moderate acne

C. A. MORTON<sup>1</sup>, R. D. SCHOLEFIELD<sup>2</sup>, C. WHITEHURST<sup>3</sup> & J. BIRCH<sup>3</sup>

<sup>1</sup>Department of Dermatology, Falkirk Royal Infirmary, Falkirk, <sup>2</sup>Sequani Consumer, Vine House, New Street, Ledbury, Herefordshire and <sup>3</sup>Photo Therapeutics Ltd, Station House, Stamford New Road, Altrincham, UK

### Abstract

**Background:** The effective management of acne remains a challenge; achieving an optimal response whilst minimizing adverse events is often difficult. The rise in antibiotic resistance threatens to reduce the future usefulness of the current mainstay of therapy. The need for alternative therapies remains important. Phototherapy has previously been shown to be effective in acne, with renewed interest as both endogenous and exogenous photodynamic therapies are demonstrated for this condition. **Objectives:** To determine the effect of narrowband blue light in the reduction of inflammatory and non-inflammatory lesions in patients with mild to moderate acne and to evaluate patient tolerance of the therapy. **Methods:** We performed an open study utilizing a blue LED light source in 30 subjects with mild to moderate facial acne. Two weeks after screening, lesions were counted and recorded by lesion type. Over 4 weeks, patients received eight 10- or 20-minute light treatments, peak wavelength 409–419 nm at 40 mW/cm<sup>2</sup>. Assessments were taken at weeks 5, 8 and 12 and lesion counts were recorded. Repeated measures-ANOVA and Dunnett's tests, respectively, allowed assessment of the different scores over time and permitted comparison of mean counts. **Results:** An overall effect on inflammatory counts was observed at week 5, and a statistically significant decrease in inflamed counts was detected at the week 8 assessments, which continued to week 12. There was little effect on non-inflamed lesions. The treatment was well tolerated with adverse events experienced generally rated as being mild and usually self-limiting. **Conclusions:** Eight 10- or 20-minute treatments over 4 weeks with a narrowband blue light was found to be effective in reducing the number of inflamed lesions in subjects with mild to moderate acne. The treatment had little effect on the number of comedones. The onset of the effect was observable at the first assessment, at week 5, and maximal between weeks 8 and 12. Blue light phototherapy using a narrowband LED light source appears to be a safe and effective additional therapy for mild to moderate acne.

**Key words:** Acne vulgaris, phototherapy, narrowband blue light, *Propionibacterium acnes*

### Introduction

Acne vulgaris is estimated to affect 95% and 83% of 16 year-old boys and girls, respectively, with the disease necessitating physicians' help in around 20% (1). Census data and prevalence rates suggest that approximately 40 million 12–24-year-old US individuals (85% of that population group) may have some form of acne (2). Post-adolescent acne is an increasingly common clinical presentation, usually resulting from persisting acne and occasionally from true late-onset (over 25 years) acne (3).

Many patients fail to respond adequately to, and develop problematic side effects from, currently available agents. Resistance of *Propionibacterium acnes* to antibiotics is estimated to have risen from 20% in 1978 to 62% in 1996 (4). A recent report highlighted the need to further improve outcomes in acne. The negative effects of acne on emotional well-being and social function are well-recognized, even in some patients with mild acne (5,6). Sunlight has beneficial effects on acne and attempts to harness this effect now target the absorption wavelengths of

the endogenous porphyrins of *P. acnes* delivered at the correct dose (7). The need for alternative, well-tolerated, non-antibiotic therapies, combined with developments in light technology, led us to assess the efficacy of a novel blue light source in mild to moderate acne.

### Methods

#### Subjects

Thirty subjects (53% male, 47% female, mean age 18, range 16–52 years old) were recruited with mild to moderate facial acne as defined by the Global Acne Grading system (8). The first 14 subjects were randomized to receive either 10 minutes light exposure (24 J/cm<sup>2</sup>) or 20 minutes (48 J/cm<sup>2</sup>), in order to compare the efficacy and safety of the two regimes. As no significant differences in adverse events were observed, the remaining 16 subjects were treated for 20 minutes (48 J/cm<sup>2</sup>).

For this study, subjects had not used topical, oral or systemic treatments for 2 weeks and had not

Table I. Average reduction in papules and pustules at 1, 4 and 8 weeks after the last treatment for all cohorts.

Parameter	Mean lesion count (range)	Average reduction (range)
Total inflamed lesions (baseline)	27 (8–105)	
First assessment: 1 week post treatment	21 (4–57)	–25% (18–70%)
Second assessment: 4 weeks post treatment	13 (1–35)	–53% (39–85%)
Third assessment: 8 weeks post treatment	11 (0–32)	–60% (48–89%)

received oral retinoids for 6 months. All subjects gave informed consent to the treatment and had been pre-screened before inclusion in the study. Treatments were administered between January and April 2003.

#### Light source

A light source comprising a hinged planar array of light emitting diodes was used for this study. Subjects received all their treatments from LED prototype lamps with a bandwidth of 20 nm centred within the range of 409–419 nm with an optimized dose of 48 J/cm<sup>2</sup> and intensity of 40 Mw/cm<sup>2</sup> (Omnilux blue, Photo Therapeutics Ltd, Altrincham, Manchester, UK).

#### Treatment

Subjects were treated at Sequani Ltd, Ledbury, Herefordshire, UK. Each subject received a 10- or 20-minute exposure to the blue light, twice weekly (3–4 days interval between treatments) for a period of 4 weeks (a total of eight treatments). The unit was positioned approximately 5–10 cm from the subject's face for the duration of the treatment.

#### Assessment

Baseline assessments of acne grading and facial erythema were recorded. The numbers of comedones (open and closed), papules and pustules were recorded.

Assessments of acne lesion count and facial erythema were made 1, 4 and 8 weeks after the final treatment, with some subjects undergoing a further voluntary assessment at 12 weeks. Assessments were carried out by the same physician. At each assessment the subject's opinion on the treatment tolerance and grading of acne improvement was recorded.

#### Statistical methods

Repeated measures (RM)-ANOVA and Dunnett's test were used for analyses of the inflammatory count and the total count. The statistical power of the analysis was 57%, the significance level used (alpha) was 0.05. Independent variables included sex, age, skin type, time and relevant two-way interactions.

#### Results

Table I shows the average reduction in inflammatory and non-inflamed lesions at 5, 8 and 12 weeks after the first treatment for all cohorts. The clinical improvement observed is shown in Figures 1 and 2. Figure 3 profiles the reduction in average inflammatory counts during the assessment period. At the additional voluntary assessment at week 16 (8 weeks post treatment), the average clearance of inflammatory lesions was 64%. There was no observed reduction in non-inflammatory lesions (Table II).

The pattern of improvement varied between individuals. This was reflected in the time to reach

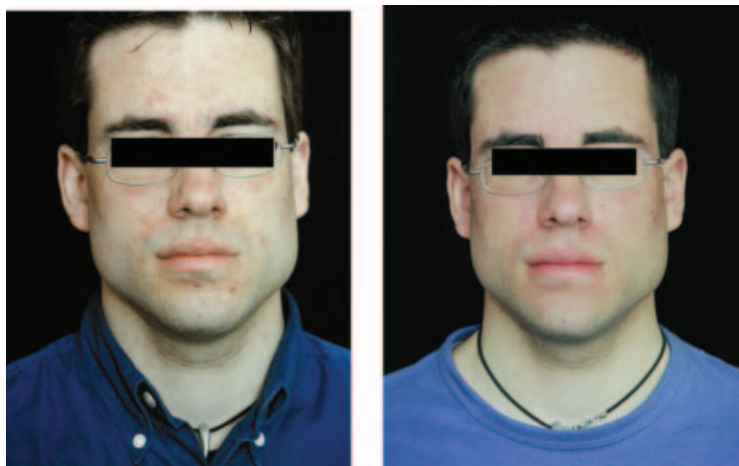


Figure 1. Baseline appearance and at assessment 4 weeks post treatment – an optimum response of 89% reduction in inflamed lesions.

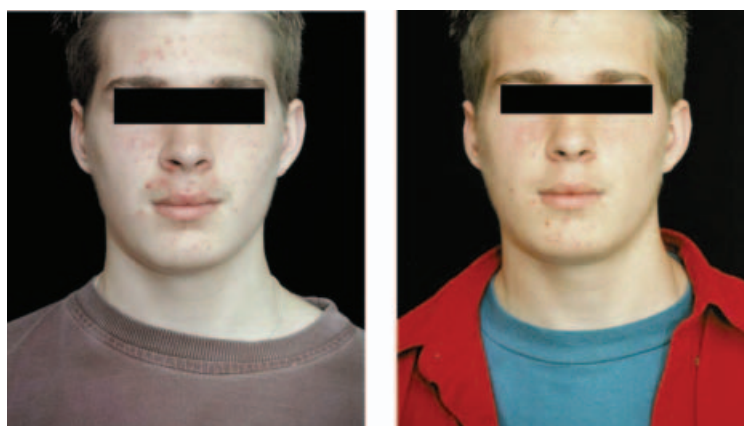

Figure 2. Baseline appearance and at assessment 8 weeks post treatment – an optimum response of 58% reduction in inflamed lesions.

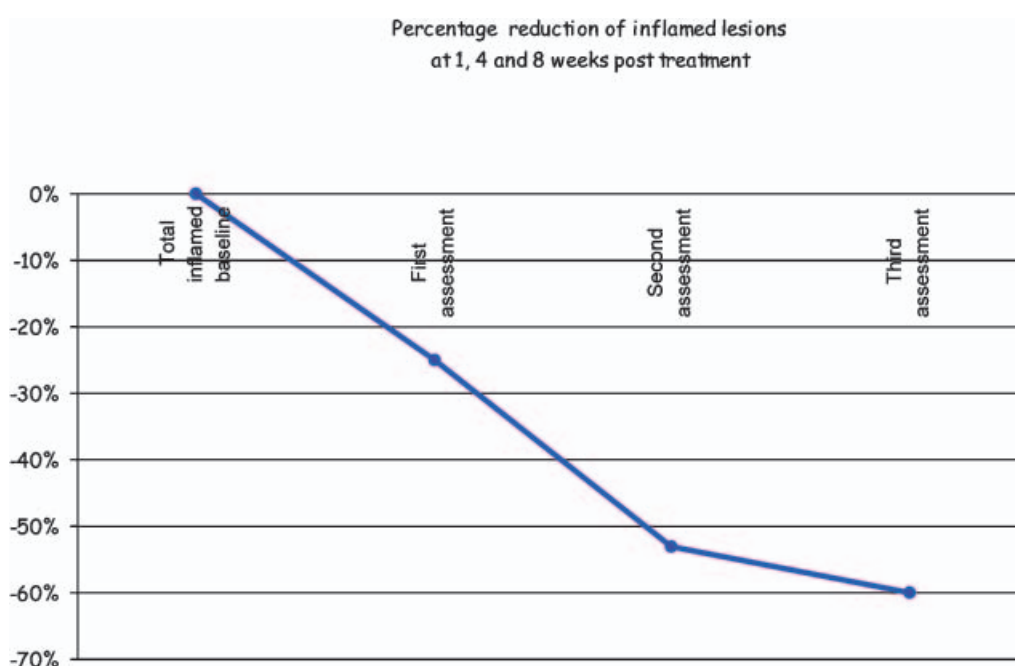


Figure 3. Percentage reduction of inflamed lesions at 1, 4 and 8 weeks post treatment.

optimum clearance for each subject. In all, 28% of subjects achieved optimum clearance at 4 weeks post treatment (average clearance 76%), 55% at 8 weeks (average clearance 71%), and 17% at 12 weeks (average clearance 73%). Using this optimum

Table II. Average reduction in non-inflamed lesions at 1, 4 and 8 weeks after the last treatment for all cohorts.

Parameter	Mean lesion count (n)	Average reduction
Total non-inflamed (baseline)	49	...
First assessment: 1 week post treatment	64	+31%
Second assessment: 4 weeks post treatment	51	+4%
Third assessment: 8 weeks post treatment	50	+2%

clearance data over the study period, the average reduction in inflammatory lesions was 73%.

RM-ANOVA provided highly significant evidence of a difference between one or more of the time points ( $p=0.001$ ). Dunnett's test indicated that the counts recorded for the 8- and 12-week assessments were significantly different to the baseline counts. The size of the study population prevented statistical comparison between the two light doses used. There was little effect on non-inflammatory (comedonal) lesions.

The total mean count of inflamed and non-inflamed lesions demonstrated an increase over baseline at week 5 and then fell to 80% of baseline by week 12. Subjects' rating of the treatment efficacy reflected the high clearance rates. Only one subject rated the treatment efficacy as poor and 75% of the group said that they would use the treatment again. Only one subject said that they would not use it

again. There were only minor reported adverse events; one subject withdrew due to personal reasons not connected with the study. The reported minor adverse events were self-limiting and ranged from slight redness after treatment,  $n=16$  (53%); dryness of skin,  $n=4$  (13%) and mild pruritus,  $n=5$  (16%).

## Conclusion

Phototherapy with visible light has been previously shown to have a beneficial effect in acne (7). Although ultraviolet light and sun exposure can be beneficial, avoidance of the potential risks of UV radiation has led to more detailed studies of which wavelengths are of therapeutic importance. *In vitro* studies have shown that irradiation of *P. acnes* colonies with blue visible light leads to photo-excitation of the bacterial porphyrins, stimulating singlet oxygen production and the endogenous photodynamic destruction of *P. acnes* (9). The predominant porphyrins produced by *P. acnes* are coproporphyrin III and protoporphyrin IX (PpIX) (10,11). These porphyrins mainly absorb blue visible light around 400–420 nm with the peak of coproporphyrin III absorption at 415 nm (12).

In this study we have been able to demonstrate that blue light therapy at 409–419 nm significantly reduces inflammatory acne lesions. Light absorption by target cells also induces changes in membrane permeability leading to proton influx and dissipation of pH gradients across the cell membrane, inhibiting the proliferation of *P. acnes* (13). Inhibition of proliferation as well as photodynamic destruction of *P. acnes* could play a significant part in the response of inflamed acne skin to blue light.

There was a different response pattern across the study group and the time to reach the optimum clearance differed between subjects. Irradiation of cells by light at a specific controlled wavelength lasts on a timescale of minutes and stimulates the primary responses. Therefore the resultant effects observed days or weeks later must be explained by a group of secondary reactions that occur after the stimulation of the cells and subsequent primary response (14).

A study in patients with mild to moderate acne showed a slightly superior efficacy of a combination of red and blue light phototherapy (delivered simultaneously) over blue light alone in the improvement of both comedonal and inflammatory acne, although this was only statistically significant for inflammatory lesions (15). Red light has been proven to have an anti-inflammatory action via promoting cytokine release from macrophages. Daily 15-minute treatments over 12 weeks achieved a mean reduction in inflammatory lesions of 76% using blue-red phototherapy compared with 63% for blue light. Over the prolonged study period a similar improvement in comedones was noted for the blue-red as well as the blue light only groups. Interestingly

Karu demonstrated that red and blue light delivered simultaneously had inhibitory effects on cell lines, compared with red and blue light delivered independently (14). A high intensity narrowband metal halide source of blue light with a peak emission of 407–420 nm has recently been studied in patients with mild or moderate acne. Treatments were carried out twice weekly for up to 5 weeks, with a treatment fluence of 90 mW/cm<sup>2</sup>. By week 5, the reduction in the number of skin lesions was 64% and this was sustained over a 4-week follow-up, with the greatest effect on inflammatory papules and pustules. A reduction in cultured *P. acnes* was demonstrated following irradiation (16).

The novel LED light source described in this study (FDA approved – KL030883) combines the high intensity output of narrowband blue light specifically targeting the photoactive porphyrins of *P. acnes*, with a compact portable design that permits use of an interchangeable head to use red light LED for other treatment modalities, such as skin rejuvenation and cancer PDT therapy.

Acne is a multifactorial process and combination therapy is often required to optimize response (17). Interest in phototherapy as an option for acne has fluctuated over time, reflecting clinicians' experience that sunlight or artificial UV often improves acne, but that additional active therapeutic intervention is usually still necessary. Optimizing light therapy with intense narrowband blue light enhances the potential for phototherapy in some types of acne without some of the adverse effects seen with ALA-PDT (18). Consideration is now required as regards the use of comedonal agents such as salicylic acid in conjunction with blue light therapy to provide a practical yet effective therapy combination, acceptable to today's population of acne sufferers.

We propose that blue light therapy significantly reduces inflamed acne lesions rapidly over the initial treatment period, with mild side effects, and offers an effective and safe treatment for acne vulgaris. Follow-up data indicate that the optimum clearance rates are experienced between 4 and 8 weeks post treatment with an average clearance of inflamed lesions of 73%. PDT is to be expected to be most effective against inflamed lesions, where there will be more activated inflammatory cells. Although relatively little is known about the resolution of acne, as inflamed lesions can evolve from comedones, the opposite, we presume may occur, with treated 'inflamed' lesions appearing and hence counted as non-inflamed, before actually resolving. This hypothesis would be in keeping with a subsequent stable number of non-inflamed lesions after 4 weeks post-therapy.

We were interested to note the lack of apparent difference in the efficacy of the two light doses used. Shorter treatments would clearly be preferable and will be the subject of further study to ensure optimal

efficacy with the shortest possible duration and number of treatments, recognizing compliance challenges in this typically teenage/young adult patient group. Therapies that avoid oral ingestion of medication and minimize topical applications are likely to be popular with patients as long as there is ease of access to the treatment. This study is consistent with previous reports of blue light used in acne and suggests that optimized blue light phototherapy deserves inclusion in the list of therapeutic options for patients with mild to moderate acne.

## References

- Burton JL, Cunliffe WJ, Stafford L, Shuster S. The prevalence of acne vulgaris in adolescence. *Br J Dermatol*. 1971;85:119–26.
- White GM. Recent findings in the epidemiologic evidence, classification, and subtypes of acne vulgaris. *J Am Acad Dermatol*. 1998;39(Pt 3), S34–S37.
- Goulden V, Clark SM, Cunliffe WJ. Post-adolescent acne: a review of clinical features. *Br J Dermatol*. 1997;136:66–70.
- Cooper AJ. Systematic review of *Propionibacterium acnes* resistance to systemic antibiotics. *Med J Aust*. 1998;169:259–61.
- Mallon E, Newton JN, Klassen A, Stewart-Brown SL, Ryan TJ, Findlay AY. The quality of life in acne: a comparison with general medical conditions using generic questionnaires. *Br J Dermatol*. 1999;140:672–6.
- Gollnick H, Cunliffe W, Berson D, Dreno B, Finlay A, Leyden JJ, et al. Management of acne. *J Am Acad Dermatol*. 2003;49:S1–S38.
- Cunliffe WJ, Goulden V. Phototherapy and acne vulgaris. *Br J Dermatol*. 2000;42:853–6.
- Glogau RG. Aesthetics and autonomic analysis of skin aging. *Semin Cutan Surg*. 1996;15:34–8.
- Arakane K, Rya A, Hayashi C, Masunaga T, Shinmato K, Mashiko S, et al. Singlet oxygen ( $^1\Delta_g$ ) generation from coproporphyrin in *Propionibacterium acnes* on irradiation. *Biochem Biophys Res Commun*. 1996;223:578–82.
- Lee WL, Shalita AR, Poh-Fitzpatrick MB. Comparative studies of porphyrin production in *P. acnes* and *P. granulosum*. *J Bacteriol*. 1978;133:811–15.
- Kjeldstad B, Johnsson A, Sandberg S. 1984 Influence of pH on porphyrin production in *P. acnes*. *Arch Dermatol Res*. 1984;276:396–400.
- Kjeldstad B, Johnsson A. An action spectrum for blue and near ultraviolet inactivation of *P. acnes*. *Photochem Photobiol*. 1986;43:67–70.
- Futsaether CM, Kjeldstad B, Johnsson A. Intracellular pH changes induced in *Propionibacterium acnes* by UVA radiation and blue light. *J Photochem Photobiol B*. 1995;31:125–31.
- Karu TI. Primary and secondary mechanisms of action of visible to near-IR radiation on cells. *J Photochem Photobiol B*. 1999;49:1–17.
- Papageorgiou P, Katsambas A, Chu A. Phototherapy with blue (415 nm) and red (660 nm) light in the treatment of acne vulgaris. *Br J Dermatol*. 2000;142:973–8.
- Kawada A, Aragane Y, Kameyama H, Sangen Y, Tezuka T. Acne phototherapy with a high-intensity, enhanced, narrow-band, blue light source: an open study and in vitro investigation. *J Dermatol Sci*. 2002;30:129–35.
- Webster GF. Acne vulgaris. *BMJ*. 2002;325:475–9.
- Morton CA, Brown SB, Collins C, Ibbotson S, Jenkinson H, Kurwa H, et al. Guidelines for topical photodynamic therapy: report of a workshop of the British Photodermatology Group. *Br J Dermatol*. 2002;146:552–67.